

Case Report

Cavernous sinus dural arteriovenous fistula completely occluded by transarterial NBCA embolization with balloon assisted technique

Yasunari NIIMI¹⁾ Joon K. SONG¹⁾ Alejandro BERENSTEIN¹⁾

1) Center for Endovascular Surgery, Institute for Neurology and Neurosurgery Roosevelt Hospital

●Abstract●

Purpose: We report a case of cavernous dural arteriovenous fistulas (dAVFs) completely occluded by transarterial embolization with n-butyl cyanoacrylate (NBCA) as the embolic agent and using balloon assisted technique.

Case: A 37-year-old woman presented with right conjunctival injection, proptosis and diplopia. She was initially treated with right carotid compression without improvement of symptoms. Two weeks prior to admission to our institution, she experienced acute worsening of the symptoms. Her right intraocular pressure was 31mmHg on admission. MRI showed right cavernous dAVFs. Angiographic study showed dAVFs to the right anterior inferior cavernous sinus supplied by the branches of the right internal and external carotid arteries. Endovascular treatment was performed by a bi-femoral approach. A microballoon catheter was placed in the right internal carotid artery across the cavernous segment. A microcatheter was wedged into the carotid branch of the ascending pharyngeal artery. Under balloon inflation to close the origin of the C4 feeder to the fistulas, 0.7cc of 25% NBCA mixed with ethiodol was injected from the wedged microcatheter, resulting in complete occlusion of the fistulas. The patient showed immediate improvement of the symptoms and her right intraocular pressure was normal one week after treatment.

Conclusion: Trans-arterial embolization may be the best treatment option for selected cases of cavernous dAVFs. Balloon protection of the internal carotid artery may be necessary for aggressive trans-arterial embolization to prevent NBCA migration into the cerebral circulation through the anastomosis between the external and internal carotid arteries.

●Key Words●

cavernous dural fistula, trans-arterial embolization, NBCA

<Correspondence Address : 1000 Tenth Avenue 10G, New York, NY 10019 U.S.A. E-mail: yasuniimi@aol.com>

(Received January 17, 2008 : Accepted January 23, 2008)

Cavernous dural arteriovenous fistulas (dAVFs) are usually multiple fistulas supplied by dural branches of the internal and external carotid arteries, draining to the unilateral or bilateral cavernous sinus. Endovascular treatment is the first choice of treatment for a symptomatic lesion causing increased intra-ocular pressure, diplopia, proptosis and conjunctival injection. Trans-arterial embolization often results in partial occlusion because of the small size and complexity of the feeders. We report a case of cavernous dAVFs successfully treated by one trans-arterial injection of NBCA with balloon protection of the internal carotid artery.

Case report

Four months post-partum, a 37-year-old woman presented with right eye bulging, redness, and diplopia. MRI study showed prominent vessels in the right cavernous sinus, suggesting cavernous dAVFs. Initially carotid compression was tried but this did not significantly improve her symptoms.

Two weeks before admission, she developed acute worsening of right eye bulging and redness. On physical examination, she had significant right proptosis and conjunctival injection with mild restriction of the eye movement and diplopia in all directions (Fig. 1). The right eye intra-ocular pressure was 31 mmHg with normal visual acuity. The decision was made to perform angiographic study with intent to treat the right cavernous dAVFs under general anesthesia. Angiographic study demonstrated right cavernous dural AVFs to the anterior inferior portion of the cavernous sinus with further drainage predominantly to the superior ophthalmic vein which was thrombosed distally. Feeders were C4 and C5 branches of the cavernous segment of the internal carotid artery (Fig. 2) and the external carotid artery branches including the middle meningeal artery, artery of foramen rotundum, accessory meningeal artery and ascending pharyngeal artery (Fig. 3). No supply was seen from the left side.

Following angiographic study, the decision was made to

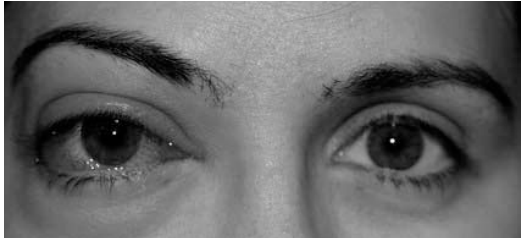

Fig. 1 Clinical picture before treatment showing significant right eye proptosis, conjunctival injection, and dilated pupil.

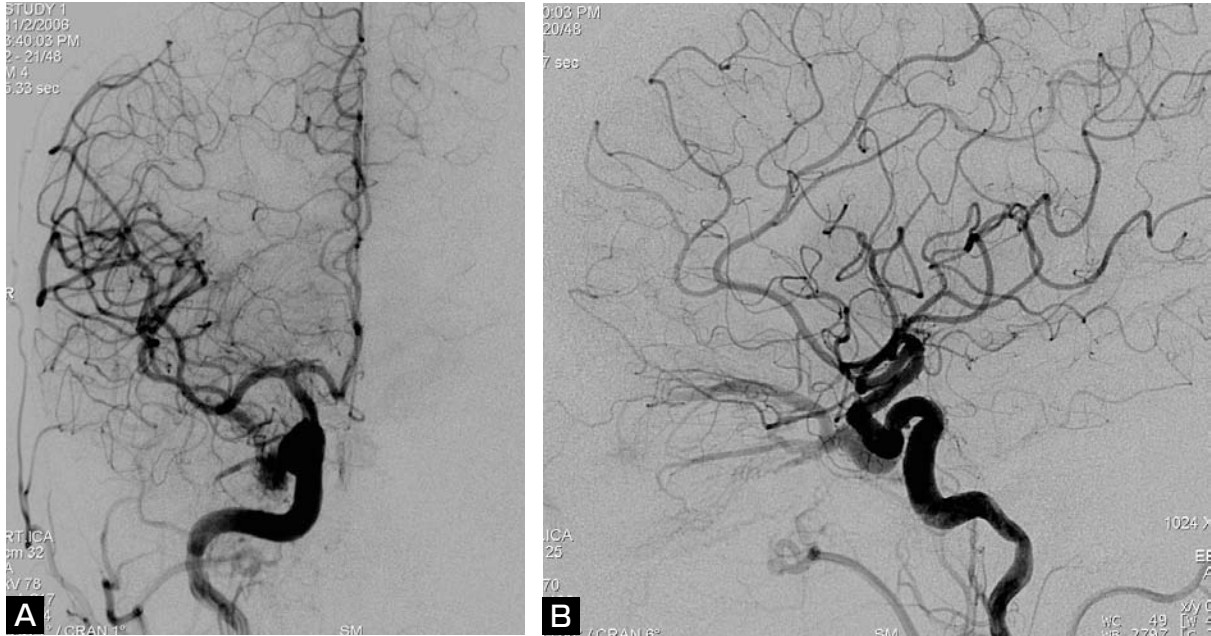


Fig. 2 Posterior anterior (PA) (A) and lateral (B) views of right internal carotid artery angiogram showing cavernous dural arteriovenous fistulas (dAVFs) supplied by cavernous branches of the internal carotid artery. The venous drainage is predominantly to the distally thrombosed superior ophthalmic vein.

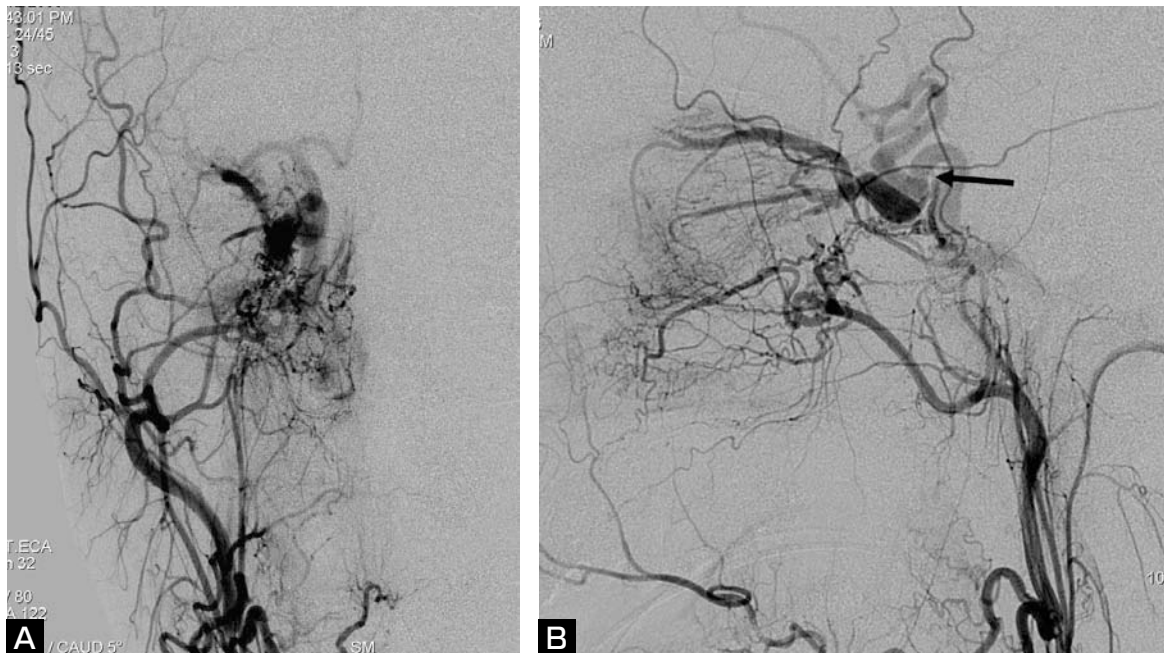


Fig. 3 PA (A) and lateral (B) views of right external carotid artery angiogram showing cavernous dAVFs. Feeders are the artery of foramen rotundum, the accessory meningeal artery, the middle meningeal artery and the ascending pharyngeal artery. Reflux of contrast material to the right internal carotid artery shows the feeder from the C4 branch which connects to the feeder from the ascending pharyngeal artery (arrow). Compare with 2B and 5B.

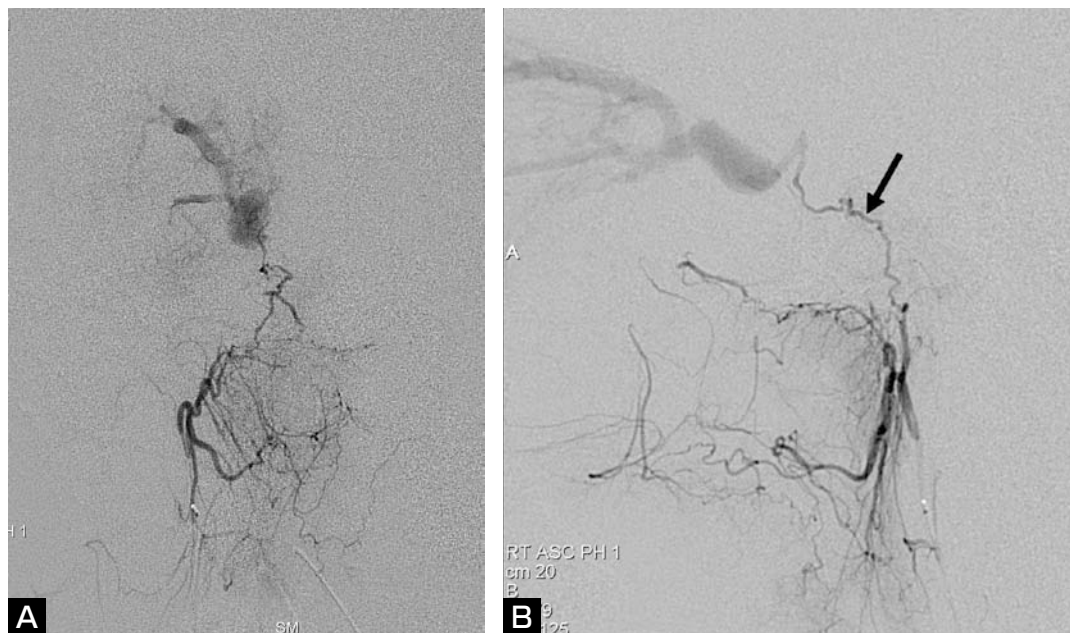

Fig. 4 PA (A) and lateral (B) views of super-selective angiogram of the pharyngeal branch of the ascending pharyngeal artery. The carotid branch (arrow) is supplying the cavernous dAVFs.

perform trans-arterial embolization. As a guiding catheter, a 5-Fr Envoy catheter (Cordis Neurovascular Inc., Miami Lakes, FL.) was placed at the origin of the right ascending pharyngeal artery. A Prowler 10 microcatheter (Cordis Neurovascular Inc., Miami Lakes, FL.) was advanced into the pharyngeal branch of the ascending pharyngeal artery. Super-selective digital subtraction angiogram showed the carotid branch supplying the dAVFs (Fig. 4). The microcatheter was further advanced distally to wedge it into the carotid branch. Super-selective angiogram showed dAVFs with flow control in the feeder. Forceful injection showed transient opacification of the C4 and C5 branches of the internal carotid artery with washout of the contrast by non-opacified blood from these branches. At this point, the decision was made to perform trans-arterial embolization using n-butyl cyanoacrylate (NBCA) with balloon protection of the internal carotid artery. The second femoral sheath was placed in the left groin, through which another 5Fr Envoy catheter was placed in the right internal carotid artery. Through this catheter, a Hyperform balloon catheter (Micro Therapeutics, Inc. Irvine CA) 7mm x 7mm was placed across the largest C4 feeder to the AVFs. Under systemic heparinization, the balloon was inflated to temporarily occlude the origin of the C4 feeder as well as the internal carotid artery to prevent NBCA to migrate into the internal carotid artery through the anastomosis (Fig. 5A-C). This was followed by slow injection of 25% TruFill NBCA (Cordis Neurovascular Inc. Miami

Lakes, FL) from the microcatheter wedged into the carotid branch of the ascending pharyngeal artery. A total volume of 0.7cc of NBCA mixture was injected, occluding the venous side of the AVFs (Fig. 5D). Angiographic study of the right internal, external and common carotid arteries showed complete occlusion of the dAVFs (Fig. 6). The procedure time from the first contrast injection for the diagnostic angiogram to the last angiogram after the embolization was one hour and 26 minutes.

The patient showed immediate improvement of her visual symptoms after the embolization (Fig. 7) and was discharged next day. One week after treatment, the patient had no double vision and had normal intraocular pressure with remaining mild proptosis.

Discussion

Endovascular treatment for cavernous dAVFs can be performed by trans-arterial, trans-venous, or combination of both approaches. We believe that NBCA is currently the best embolic agent for trans-arterial embolization of cavernous dAVFs. Particles and coils tend to result in proximal occlusion of the feeders and cause recanalization of the fistulas through the collateral circulation, which makes later trans-arterial endovascular treatment difficult⁴). Onyx (Microtherapeutics, Inc. Irvine CA) is a promising agent for dAVFs in general but its role for cavernous dAVFs has not been established because of risks to damage the cranial

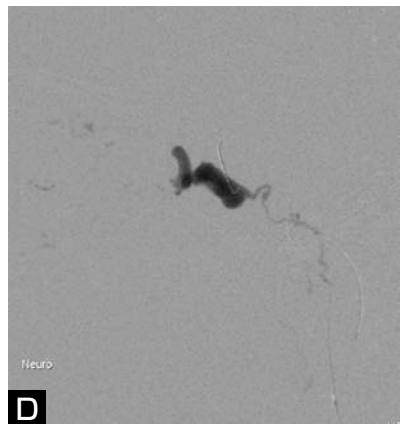
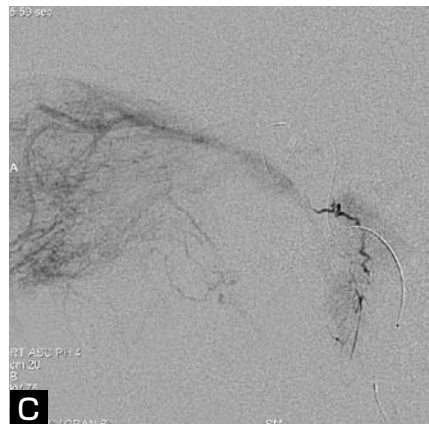
nerves. In order to obtain the best treatment result by trans-arterial embolization, diluted NBCA should be injected through a microcatheter wedged in the feeder to penetrate into the venous side of the fistulas^{3,4)}. The major risks of trans-arterial embolization are cerebral ischemia by migration of the embolic agent into the cerebral circulation through the anastomosis between the external and internal carotid arteries and cranial nerve damage by occluding nutrient vessels to the cranial nerves. Cranial nerves II to XII are potentially at risk by trans-arterial embolization²⁾, depending on the feeder embolized. Among them, the carotid branch of the ascending pharyngeal artery carries the least risk to cranial nerves because this vessel does not have direct supply to the cranial nerves, although it can potentially anastomose with vessels supplying III to VI cranial nerves and also supply the autonomic nervous system²⁾. We have never experienced damage to the cranial nerves or the autonomic nerves by embolizing through this vessel. The largest risk of embolization through this vessel is migration of the embolic

agent into the internal carotid artery because it anastomoses with the recurrent artery of foramen lacerum originating from the cavernous segment of the internal carotid artery as seen in this case. Therefore, we protected the internal carotid artery with the inflated balloon during the injection of the NBCA into this vessel.

If vascular anatomy of the cavernous dAVFs is relatively simple, and especially when the venous drainage of the dAVFs is predominantly anteriorly to the superior ophthalmic vein, trans-arterial embolization may be the easiest treatment even if there are multiple fistula sites like in this case. If the vascular anatomy is complex with multiple venous drainage from the cavernous sinus, trans-arterial embolization is rarely curative even if an embolic agent is injected through a microcatheter wedged into the feeder. The risk of trans-arterial embolization is higher when NBCA needs to be injected through multiple feeders. In such cases, trans-venous embolization should be considered the first choice of treatment¹⁾.

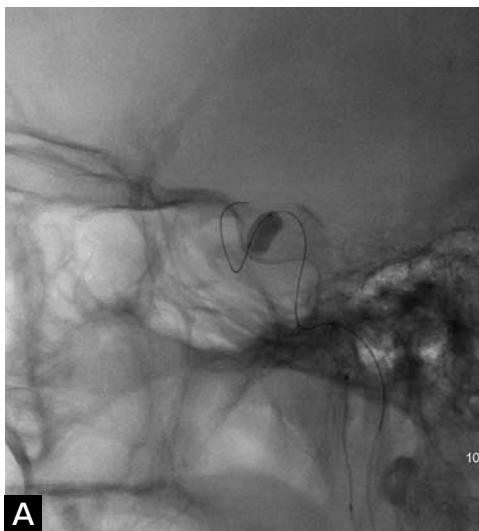

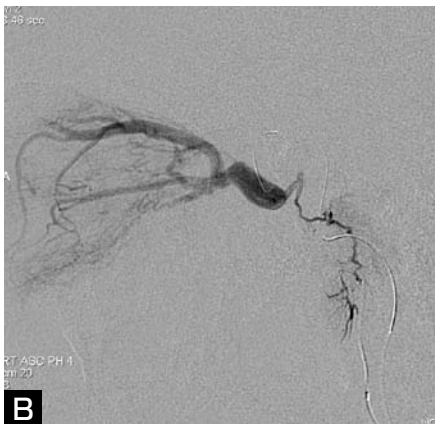Fig. 5 (A) Lateral view of the non-subtracted image of the skull showing a microballoon inflated in the horizontal cavernous segment to occlude the internal carotid artery and the origin of the C4 feeder to the cavernous dAVF. **B, C** : Lateral view of the super-selective angiogram of the carotid branch of the ascending pharyngeal artery in the early (**B**) and late (**C**) phases. The internal carotid artery is temporarily occluded with a microballoon. The early phase (**B**) shows the cavernous dAVFs. The late phase (**C**) shows stagnation of the contrast material in the carotid branch indicating the wedged micocatheter. The cavernous dAVFs are no longer opacified due to washout of contrast material by non-opacified blood though the internal and other external carotid artery feeders. **D**: Cast of NBCA injected from the carotid branch of the ascending pharyngeal artery with a microballoon inflated in the internal carotid artery. NBCA is penetrating to the anterior cavernous sinus and the proximal portion of the superior ophthalmic vein.



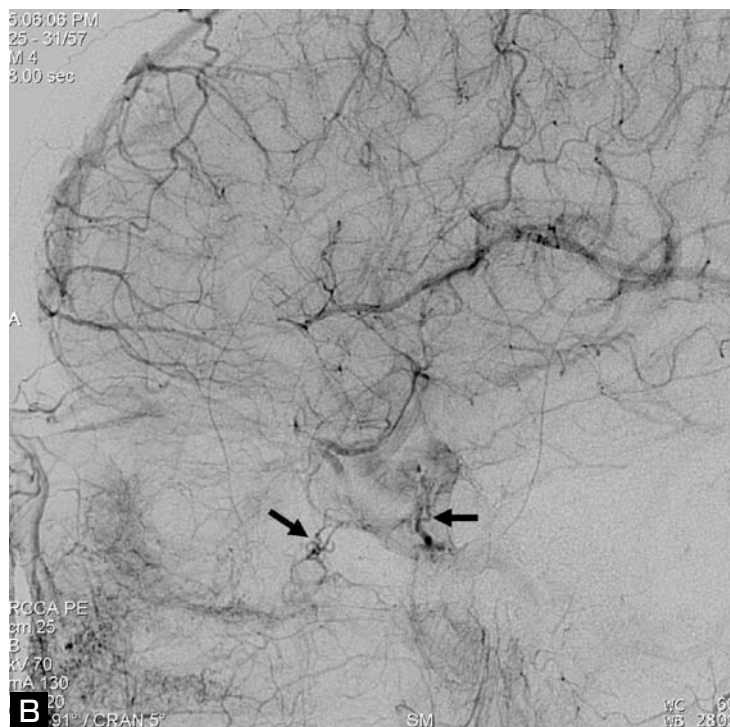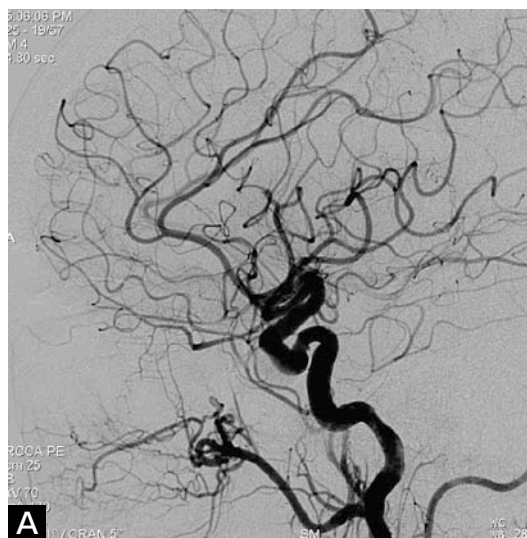


Fig. 6 Lateral views of right common carotid artery angiogram in the early (A) and late (B) phases after embolization. The cavernous dAVFs are completely occluded with stagnation of contrast material in the external carotid artery feeders (arrows).

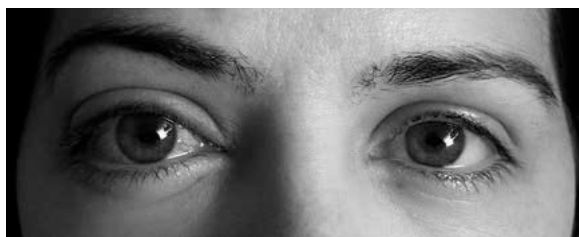

Fig. 7 Clinical picture one day after treatment showing significant improvement of proptosis and conjunctival injection.

Conclusion

Trans-arterial embolization with NBCA can be a safe and efficient way of treating selected cases of cavernous dAVFs. Careful selection of embolization technique based on thorough analysis of vascular anatomy of the lesion is mandatory for successful treatment of cavernous dAVFs.

References

- 1) Halbach VV, Higashida RT, Hieshima GB, et al: Transvenous embolization of dural fistulas involving the cavernous sinus. *AJNR* 10:377-383, 1989.
- 2) Lasjaunias P, Berenstein A, TerBrugge KG: *Surgical Neuroangiography vol.1*. Second Ed. Berlin Heidelberg New York, Springer-Verlag, 2001, 387-477.
- 3) Nelson PK, Russel SM, Woo HH, et al: Use of a wedged microcatheter for curative transarterial embolization of complex intracranial dural arteriovenous fistulas: indications, endovascular technique, and outcome in 21 patients. *J Neurosurg* 98:498-506, 2003.
- 4) Niimi Y, Berenstein A, Setton A, et al: Endovascular treatment of dural arteriovenous fistulas. In: Lawton MT, Gress DR, Higashida RT ed. *Controversies in Neurological Surgery*. New York, Thieme, 2006, 157-173.