

Persistent primitive dorsal ophthalmic artery associated with paraclinoid internal carotid artery aneurysm

Michihiro TANAKA¹⁾

1) Department of Neurosurgery, Kameda Medical Center

<Corresponding Address : Department of Neurosurgery Kameda Medical Center, 929 Higashi-cho Kamogawa city Chiba E-mail: michihiro@attglobal.net>

(Received March 3, 2008 : Accepted January 15, 2009)

Embryogenesis of the OA is highly complex, and atypical origin of the OA has been considered rare^{2,3,15,17}. The author illustrates a case of a persistent primitive dorsal ophthalmic artery (DOA) associated with a paraclinoid internal carotid artery (ICA) aneurysm and discusses the embryology of the OA.

Case Illustration

Case: A 55-year-old woman presented with a coincidental unruptured asymptomatic aneurysm originating from the left supero-lateral wall of the supraclinoid segment of the ICA

(Fig. 1). This aneurysm was located on the anterior clinoid process. Left internal carotid angiography showed that the ophthalmic artery (OA) arose from the intracavernous portion of the ICA and entered the orbital cavity via the superior orbital fissure (SOF). This was also confirmed with high resolution multi detector CT and could be recognized as a persistent of the ILT (infero lateral trunk).

Discussion

According to Padgett¹², a branch of the ICA, called the primitive DOA, emerges in the sequential development of the

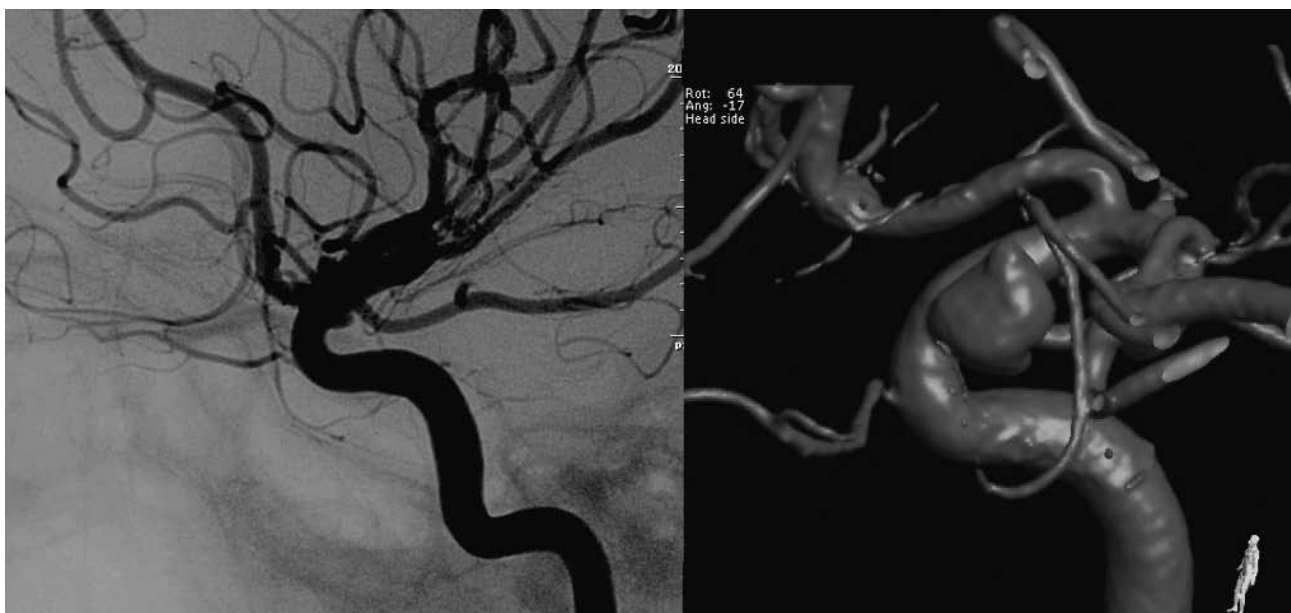

Fig. 1 Digital subtraction angiography (lateral view, left) and 3D rotation angiography (oblique view, right) showing that the ophthalmic artery comes from the intracavernous portion of the ICA and runs through the SOF. Note the atypical origin and course of the ophthalmic artery.

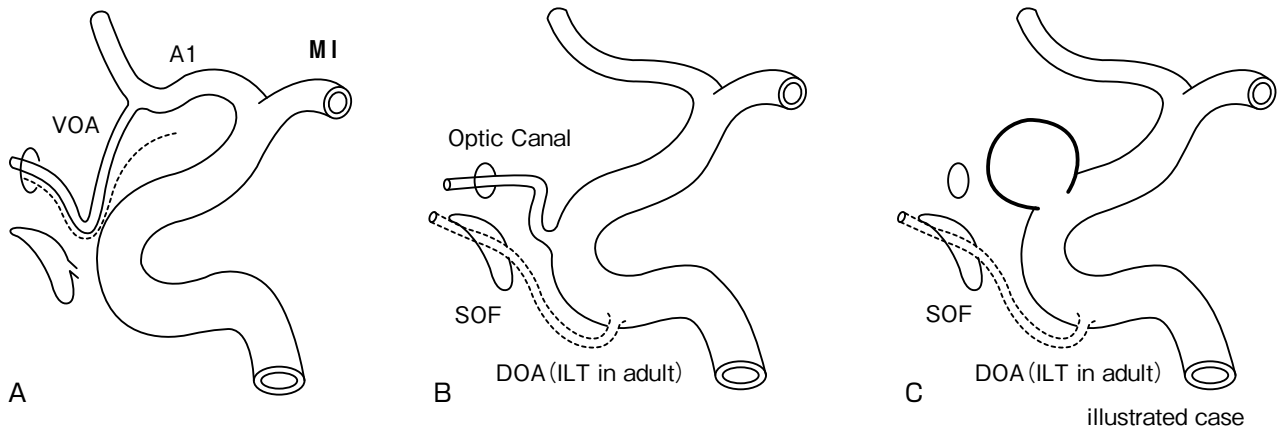


Fig. 2 Schematic representation of regression of the VOA and persistent DOA

A : The proximal part of the VOA disappears rapidly at the 8-mm stage of the embryo, and the vessel then arises from the ICA, as in the adult configuration.

B : This is the normal development and configuration of the DOA and the adult type of the OA. The DOA regresses (dotted line) and becomes the infero lateral trunk (ILT).

C : Schematic representation of the illustrated case.

cerebral arterial vasculature of an embryo/fetus at 4-mm crown-rump length. The orbit consists of three components: first is the retina (peripheral nervous system), second is the optic nerve (central nervous system), and third are the muscles and glands (periorbital structures). The blood supplies to these components reflect their different natures^{4,5,6,9,11}.

Vascularization of the optic cup is derived from two branches of the primitive ICA, called the primitive ventral ophthalmic arteries (VOA) and the DOA. The VOA arises from the future anterior cerebral artery (ACA), and the DOA arises from the carotid siphon^{1,10}. Later, these arteries anastomose near the optic nerve. The VOA makes an additional anastomosis with the supracavernous portion of the ICA^{5,10,13,15}.

At the 4-8 mm stage, these two arteries supply the orbit. The VOA from the ACA through the optic canal gives off the central retinal artery and the nasal ciliary artery, and the other DOA from the ICA (carotid siphon) via the SOF gives off the temporociliary artery (Fig. 2).

This final configuration gives rise to the primitive ophthalmic artery (POA)^{16,17}. When the embryo reaches 18 mm, the stapedia artery, which arises from the primitive hyoidal branch of the petrous ICA, gives rise to the maxillo-facial and supraorbital branches^{5,6,16}. When the embryo reaches 20 mm, the supraorbital branch of the stapedia artery forms an anastomosis with the primitive (future permanent) OA.

At the 40-mm stage of the embryo, the anastomosis is completed, and the adult configuration of the OA becomes identifiable. Until this stage, the primitive OA starts to assimilate the supraorbital branch of the stapedia artery. This branch not only supplies the intraorbital extraocular contents, but also plays a role in the formation of the middle meningeal artery (MMA)^{4,5,12}.

The origin of the OA from the ACA^{3,4,5}, the ICA bifurcation⁷, or double OAs originating from the same ICA¹⁰ can be explained with relative ease by the stages before the formation of the primitive OA (Fig. 2B). Similarly, the OA arising from the MMA, which is the most frequently reported variation³, the MMA arising from the OA¹⁶, the OA arising from the basilar artery¹⁴ and the persistent loop of the ICA, MMA, and OA¹⁷ can be explained by the role of the stapedia artery and the primitive trigeminal artery^{2,3,8}.

In normal development, the proximal part of the VOA disappears rapidly, and the vessel then arises from the ICA, as in the adult configuration. Finally, the DOA regresses and become ILT at the SOF. Although the embryology of the OA is complex, it provides an insight into understanding the variations of the OA.

References

- 1) Al-Qahtani S, Tampieri D, Brassard R: Coil Embolization of an Aneurysm Associated with an Infraoptic Anterior Cerebral Artery in a Child. *AJNR* 24:990-991, 2003.
- 2) Hamada J, Kitamura I, Kurino M, et al: Abnormal origin of

- bilateral ophthalmic arteries. *J Neurosurg* 74:287-289, 1991.
- 3) Hassler W, Zentner J, Voigt K: Abnormal origin of the ophthalmic artery from the anterior cerebral artery: neuroradiological and intraoperative findings. *Neuroradiology* 31:85-87, 1989.
 - 4) Komiyama M: *Functional Anatomy of the Brain and Spinal Vessels*. Osaka, Medica Shuppan, 2007, 124-131.
 - 5) Lasjaunias P, Berenstein A, ter Brugge KG: *Surgical Neuroangiography I, Clinical Vascular Anatomy and Variations*, Springer-Verlag, 2nd ed, 2001.
 - 6) Lasjaunias P, Moret J, Mink J: The anatomy of the inferolateral trunk (ILT) of the internal carotid artery. *Neuroradiology* 13:215-220, 1977.
 - 7) Matsumura Y, Nagashima M: Anatomical variations in the origin of the human ophthalmic artery with special reference to the cavernous sinus and surrounding meninges. *Cells Tissues Organs* 164:112-121, 1999.
 - 8) Mayer PL, Kiev EL: The ontogenic and phylogenetic basis of cerebrovascular anomalies and variants. Apuzzo MLJ ed, *Brain Surgery*. Vol 1. New York, Churchill Livingstone, 1993, 669-792.
 - 9) Newton TH, Potts DG: *Radiology of the Skull and Brain*. St. Louis, Mosby, 1974, 1333-1350.
 - 10) Nutik S, Dilenge D: Carotid-anterior cerebral artery anastomosis: case report. *J Neurosurg* 44:378-382, 1976.
 - 11) Ogawa T, Miyauchi T, Kato T, et al: Internal carotid origin of double ophthalmic arteries. *Neuroradiology* 32:508-510, 1990.
 - 12) Padgett DH: The development of the cranial arteries in the human embryo. *Contrib Embryol* 32:207-262, 1948.
 - 13) Robinson LR: An unusual human anterior cerebral artery. *J Anat* 93:131-133, 1959.
 - 14) Sade B, Tampieri D, Mohr G: Ophthalmic Artery Originating from Basilar Artery: A Rare Variant. *AJNR* 25:1730-1731, 2004.
 - 15) Spinnato S, Pasqualin A, Chioffi F, et al: Infraoptic course of the anterior cerebral artery associated with an anterior communicating artery aneurysm: anatomic case report and embryological considerations. *Neurosurgery* 44:1315-1319, 1999.
 - 16) Vignaud J, Hasso AN, Lasjaunias P, et al: Orbital vascular anatomy and embryology. *Radiology* 111:617-626, 1974.
 - 17) Willinsky R, Lasjaunias P, Berenstein A: Intracavernous branches of the internal carotid artery (ICA): comprehensive review of their variations. *Surg Radiol Anat* 9:201-215, 1987.